



Case Series

Intra cardiac echo guided papillary muscle origin Premature Ventricular Contraction (PVCs)/ Ventricular Tachycardia (VT) ablation: A case series

Selva Maheswari M¹, Sharon Jebamalar B¹, Usnish Adhikari², Deep Chandh Raja^{3*}

¹Physician Associate, Kauvery Heart Rhythm Services, Vadapalani, Chennai, Tamil Nadu

²Associate consultant cardiac electrophysiologist, Kauvery Heart Rhythm Services, Vadapalani, Chennai, Tamil Nadu

³Senior consultant & Director of cardiac electrophysiology, Kauvery Heart Rhythm Services, Kauvery hospital, Chennai, Tamil Nadu

*Correspondence

Abstract

Background: Papillary muscle (PM) premature ventricular complexes (PVCs) and ventricular tachycardias (VTs) pose unique challenges due to their deep origin, anatomical mobility, and proximity to valvular structures. Intracardiac echocardiography (ICE) has emerged as a valuable tool for real-time anatomical visualization and catheter guidance.

Key words: Papillary muscle (PM); Premature Ventricular Complexes (PVCs); Intracardiac echocardiography (ICE)

Aim: To evaluate the safety, feasibility, and outcomes of ICE-guided radiofrequency ablation of papillary muscle PVC/VT in a series of patients.

Methods: We retrospectively analyzed 10 patients (mean age ~54 years; 80% of male) with symptomatic, PM PVCs/VTs. Etiologies included ischemic heart disease (4), inflammatory cardiomyopathy (1), and idiopathic causes (6). 5 presented with premature ventricular contractions, 5 with ventricular tachycardia, and 1 with VT storm. All patients underwent high-density electroanatomical mapping. ICE guidance was employed in all cases to enhance catheter stability and visual confirmation of contact. Mapping sites included the LV anterolateral (3), LV posteromedial (5), RV posterior (1) PMs of both ventricles. Access routes included transaortic (6), transeptal (4), and right ventricular (1) approaches.

Results: Acute procedural success (suppression of clinical PVC/VT – 100%, & elimination of PVC in 80%) was achieved. No procedural complications were reported. Patients with ICE guidance had superior catheter stability and fewer energy applications. During follow-up, 10 of 11 patients remained free from recurrence.

Citation: Selva Maheswari M, Sharon Jebamalar B, Usnish Adhikari, Deep Chandh Raja. Intra cardiac echo guided papillary muscle origin Premature Ventricular Contraction (PVCs)/ Ventricular Tachycardia (VT) ablation: A case series *Kauverian Med J.* 2026;3(3):43-52

Academic Editor: Dr. Venkita S. Suresh

ISSN: 2584-1572 (Online)



Copyright: © 2025 by the authors. Submitted for possible open access publication under the terms and conditions.

Conclusion: ICE-guided PM PVC/VT ablation is a safe and highly effective strategy. Its use enhances catheter control and mapping accuracy, leading to better outcomes in these anatomically complex substrates

1. Introduction

Ablation of papillary muscle arrhythmias are technically challenging due to complex anatomy, their constant motion catheter instability. Papillary muscles are pillar like structure muscles located within the cavity of right & left ventricles, attached to the mitral & tricuspid valve leaflets respectively via Chordae tendinea. (anterior, posterior, septal) [1] Various challenging factors that affecting the success like complex anatomy, variable site of origin and exit site, inadequate catheter stability. The catheter ablation using intracardiac echo has emerged as an effective treatment option for symptomatic papillary muscle PVCs/ VT. In this case series, we present our experience of successful intra cardiac echo guided RF ablation of papillary muscle origin PVC/ VT.

Case Description: Table 1

S. No	Presentation	Ischemic heart disease	Left ventricular ejection fraction	Ablation site	Acute success	Long term recurrence
1.	41y/ M, VT	NO	60%	LV apical postero medial PAP muscle	Yes	No
2.	69/M, High PVC burden	S/P CABG	62%	LV Antero lateral PAP muscle	Yes	No
3.	83y/M, High PVC burden	TVD	65%	LV postero-medial PAP muscle	Yes	No
4.	63y/ M, VT storm	S/P PCI	35%	LV postero-medial PAP muscle	Yes	No
5.	55y/ M, High PVC burden	No	60%	LV Antero lateral PAP muscle	No	No
6.	76y/ F, High PVC burden	CAD	60%	LV postero-medial PAP muscle	Yes	Yes
7.	59y/ M, VT	No	60%	LV postero-medial PAP muscle	Yes	No
8.	34y/M, VT Inflammatory cardiomyopathy	No	60%	RV posterior PAP muscle	Yes	Yes

9.	63y/M, High PVC burden	CAD	45%	LV postero-medial PAP muscle	Yes	No
10.	57y/M, High PVC burden	No	60%	LV postero-medial PAP muscle	Yes	No

2.1 Case 1

41-year-old male with no co morbidities or no ischemic heart disease with the LVEF of 60% presented with palpitation, ECG showed ventricular tachycardia RBBB in V1; transition to negative in V2 through V6; Superior axis; – in lead 1, aVL; + in aVR. Findings suggestive of VT from LV apical region. This patient was taken for cardiac electrophysiology study, using HD-Grid catheter, high density mapping of the left ventricle from transaortic approach, was performed. Earliest potentials localised the VT to LV postero-medial papillary muscle. Under ICE-guidance and 3-d navigation, open irrigation ablation catheter was placed on the LV apical posterior papillary muscle. RF lesions were delivered at 40W for 60 sec each targeting an impedance drop of 10-15ohms. VT terminated during RF. Extensive lesions were delivered on the posterior papillary muscle. Intra cardiac Echo was used for anatomical orientation and catheter stability. No recurrence was reported on the follow up.

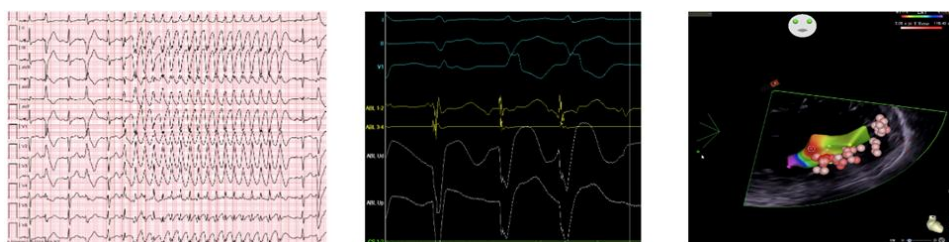


Fig (1): A- ventricular tachycardia ECG, B- ablation signals at postero medial pap muscle, C- intra cardiac echo used during ablation

2.2 Case-2

69-year-old male known to have ischemic heart disease- S/P CABG with the LVEF of 62% presented with the high PVC burden (>15%) on 24-hour Holter. The morphology suggested the PVC origin likely from papillary muscle (RBBB in V1, transition form V3-V6, superior axis). Electrophysiology study and high-density mapping using 3 d navigation system was performed. Activation map showed earliest activation preceding the surface QRS by (-20 ms) near LV anterolateral PAP muscle. Wide area of early activation noted on this muscle. Sharp prepotentials at this location of the papillary muscle were seen to precede the ventricular EGMs. Intra cardiac echo was used for anatomical correlation and for catheter stability. Extensive RF lesions were delivered at LV anterolateral PM area with the impedance drop of 10- 15 ohms, resulting in suppression of PVCs. This patient was symptom free, and no recurrence of PVCs noted during follow up Holter.

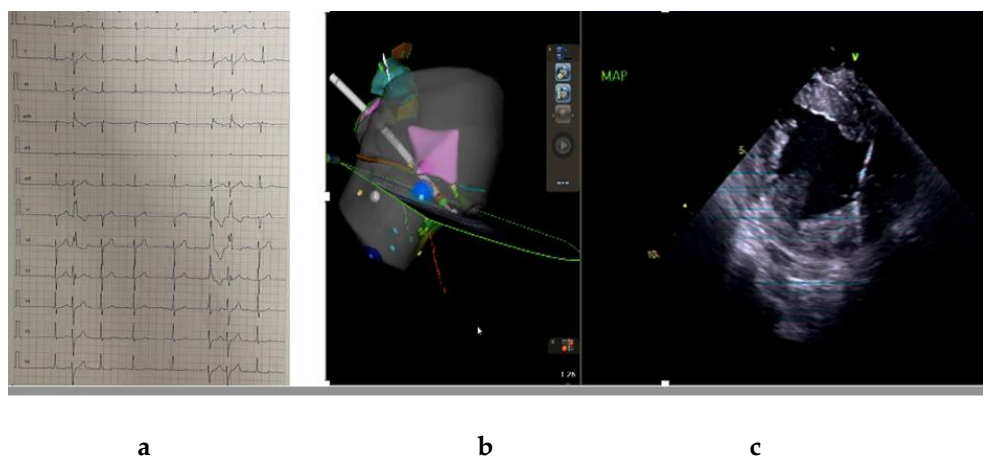


Fig (2) (a, b&c): ECG, 3-d geometry, Intra cardiac Echo

2.3 Case-3

83- year-old male known to have ischemic heart disease with the LVEF of 65% presented with the complaints of palpitations, ECG suggestive of papillary muscle originating PVC. 24 Holter was performed which showed High PVC burden (17%). During electrophysiology study PVC morphology as same as the clinical morphology, RBBB in V1; transition in V3; - in Lead II, III; + in I, - in avL. The LV geometry was created using Deca polar catheter. The PVCs was mapped using Ablation catheter. Earliest activation signals (with distinct pre-potentials) were seen -54ms preceding the PVC at lateral side of LV postero-medial papillary muscle. Using intra cardiac echo for catheter stability RF ablation was performed at 30-40W; 17cc. Each lesion was delivered targeting an impedance drop of 10%. Further lesions were delivered at the LVOT endocardium This resulted in termination of the PVCs.

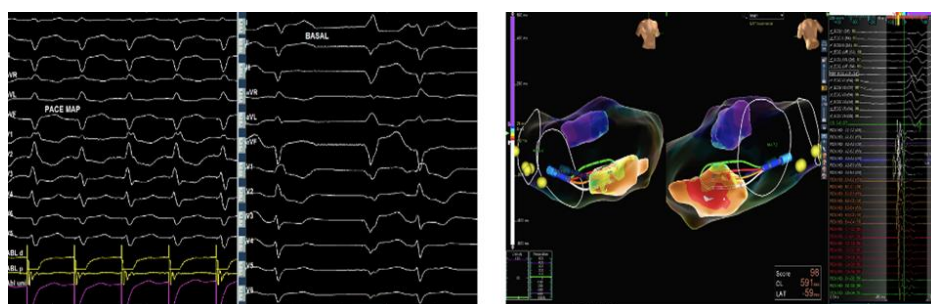

Fig (3): A Good pace map matching with basal ECG PVCs, B- ablation at posterior PAP muscle

2.4 Case-4

A 63-year male presented with acute coronary syndrome, anterior wall myocardial infarction, he underwent a multi vessel angioplasty. Post angioplasty the patient developed recurrent ventricular tachycardia (VT storm) requiring repeated direct current cardioversion. Morphology of VT showed RBBB morphology in V1, transition at V2-V3, Negative in inferior leads, isoelectric in I suggested the origin from posteromedial PM. The patient was taken up for EP study and RF ablation. Using HD grid multipolar mapping catheter and 3 d Ensite navigation system LV endocardial voltage mapping was

done. He was noted to have scar with borderline zone in posteromedial LV wall. Activation mapping during clinical PVC & pace mapping at 95% match localised the PVC at base of posteromedial PM. Flexibility irrigation catheter was used to give RF burns at 35W & 43 C. Intra cardiac echo was used for catheter stability and anatomical correlation. The site of exit and the surrounding area was successfully ablated. The patient remained symptom free with no VT recurrence on the follow up Holter. Left ventricular ejection fraction also improved to 50%.

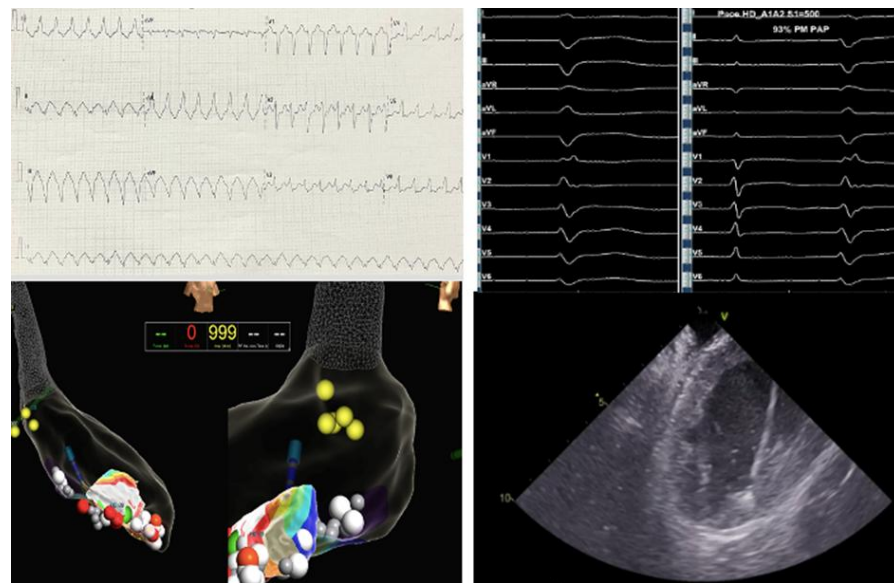


Fig (4): A- VT ECG, B- Pace map matching with clinical PVC, C- RFA at posterior PAP muscle, D- Intra cardiac echo

2.5 Case- 5

55-year male presented with recurrent palpitation and dyspnoea, with not known co morbidities or ischemic heart disease. ECG showed PVCs likely originating from PAP muscle. 24 hour Holter showed high PVC burden (20%), the patient was advised and taken for EP study, high density mapping was performed using 3d electro anatomical and intra cardiac echo guidance. The earliest activation signals were noted in LV anterolateral PM region. Extensive RF burns were delivered on that area resulted in significant suppression of PVCs.

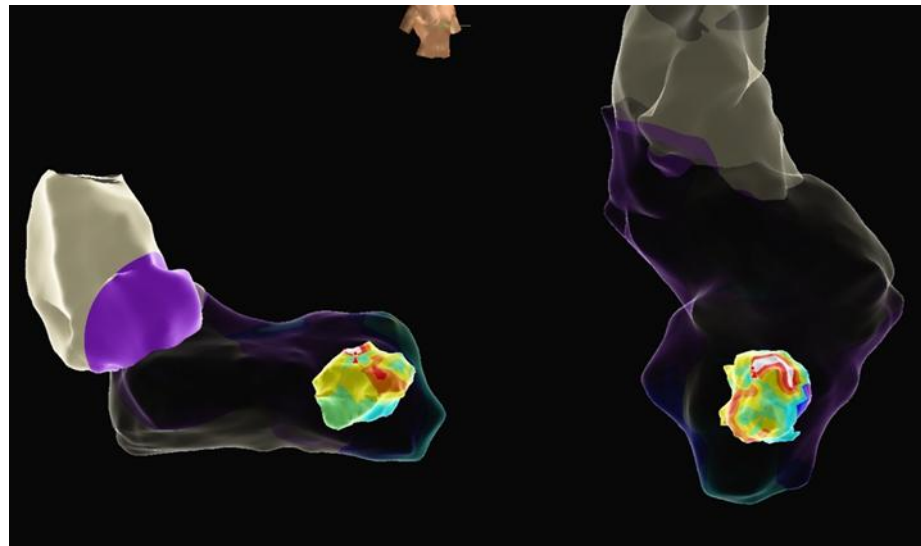


Fig (5): A- 3 d geometry of LV posterior PAP muscle

2.6. Case- 6

76-year-old female presented with the history of one episode of sustained ventricular tachycardia which was reverted with DC cardioversion with normal left ventricular ejection fraction (LVEF=60%). The VT morphology showed the origin form PAP muscle. Activation mapping showed earliest activation -60ms early at LV postero medial PAP muscle. 3d electro anatomical mapping was done and LV geometry was created. Using intra cardiac echo guidance the RF lesion was given at 30- 35W power with the impedance drop of 10- 15 ohms. PVCs got terminated during the RFA. No recurrence noted on follow up.

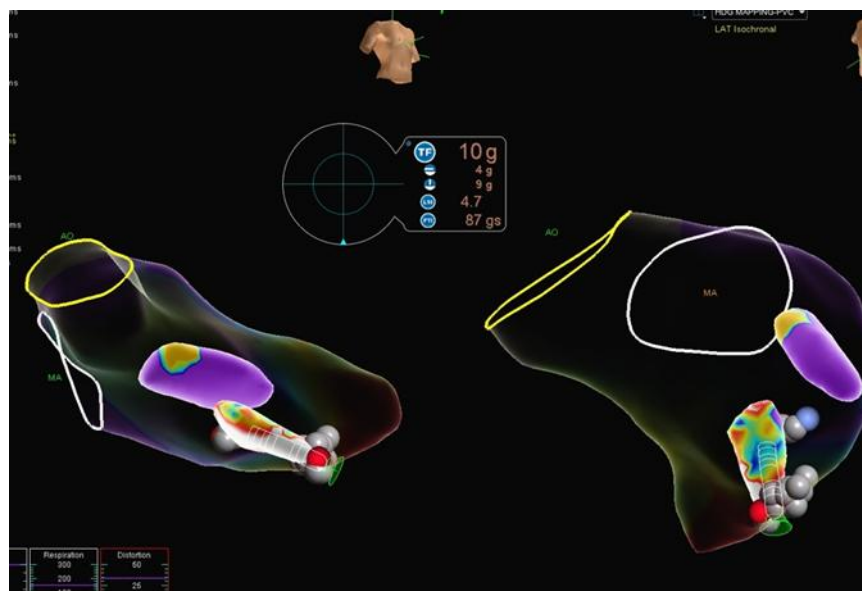


Fig (6): A- RF ablation at Antero lateral PAP muscle

2.7 Case-7

59-year male presented with the history of ventricular tachycardia which was reverted with direct current cardioversion. ECG morphology suggested the origin of VT is from PAP muscle. EP study was performed with high density electroanatomical mapping. LV geometry was created. The earliest activation signals were seen near LV posteromedial PAP muscle. Successful RF burn were delivered with the help of intracardiac echo guidance, resulted in termination of VT. No recurrence noted during follow up.

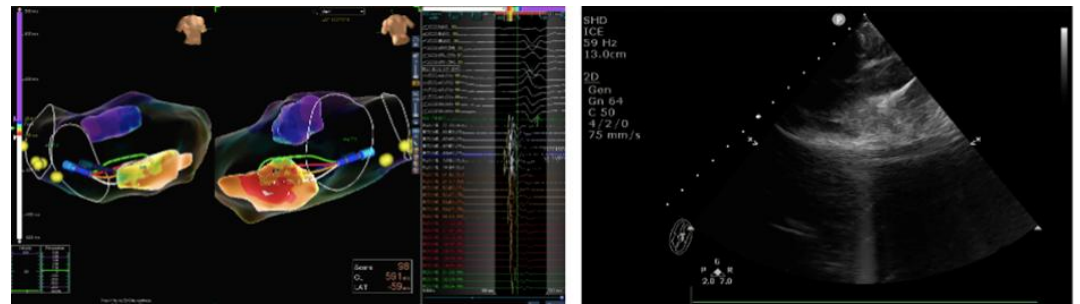


Fig (7): A- Ablation at LV posterior PAP muscle, B- Intra cardiac echo used for stability

2.8 Case-8

34-year female known to have inflammatory cardiomyopathy with the LVEF= 60%. Presented with recurrent ventricular tachycardia. Morphology of VT was- LBBB in V1; late transition in V5; Superior axis; + in Lead 1, aVL. She was taken up for EP study. During EP study easily inducible regular wide QRS tachycardia noted. Using HD grid mapping catheter and 3 d Ensite high density mapping was created both from LV & RV. Earliest potentials localized to RV posterior papillary muscle. The position of the catheter was confirmed to be on the papillary muscle using intracardiac echo. Flexibility ablation open irrigation catheter was placed on the RV posterior papillary muscle. RF lesions were delivered at 40W for 60 sec each targeting an impedance drop of 10-15ohms. Acceleration of VT with a 10/12 pace match was noted during RF. VT terminated multiple occasions during RF. Extensive lesions, guided by ICE, were delivered on the posterior papillary muscle.

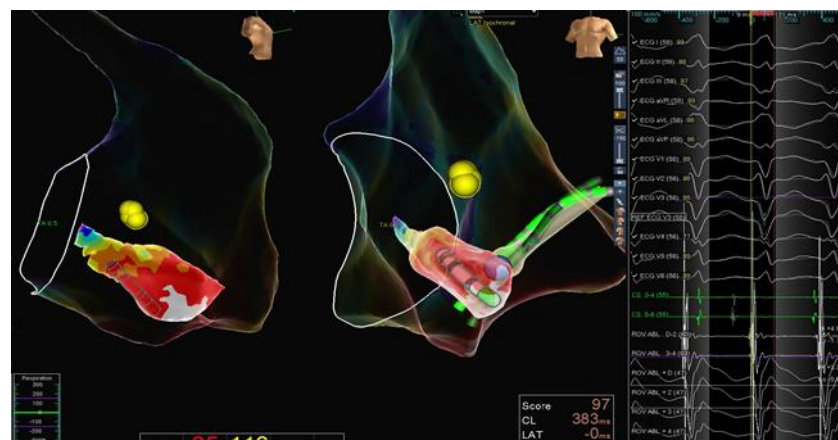


Fig (8): A- 3 d map & RF ablation at RV PAP muscle

2.9 Case- 9

63- year- old male known to have coronary artery disease and history of stroke in the past with the LVEF of 45%, presented with intermittent skipped beat and dyspnoea. 24- hour Holter showed high PVC burden of 24%. He was taken up for EP study + RF ablation. PVC morphology showed Monomorphic RBBB, R>R', right axis, transition in V3, - in lead 1, QRS- 120ms. Activation mapping was performed in the left ventricle with HD grid catheter. The fascicular P2 potentials were preceding the earliest onset of ventricular EGM on the left posterior medial papillary muscle. The potentials were preceding the QRS by 40ms. Wide region of early activation noted. Intracardiac Echo confirmed contact of the HD Grid catheter with the posteromedial papillary muscle. Pace map at the muscle at threshold revealed 12/12 match. RF burns were delivered at 40W for 60 sec each on the LV posteromedial papillary muscle, under ICE guidance. Successful suppression of PVCs noted. Further lesions were delivered on the body and base of the papillary muscle. Significant reduction of PVC burden noted during the post procedural follow up.

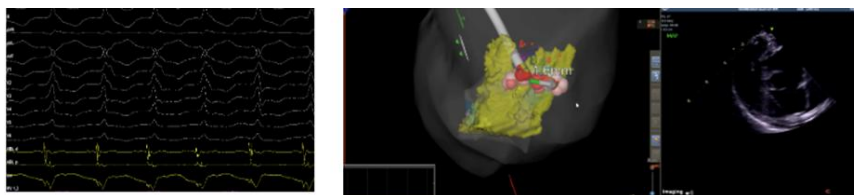


Fig (9): A- Pace map, B- RFA at LV postero medial PAP using ICE

2.10 Case-10

57- year-old male LVEF of 65% presented with the complaints of palpitations, ECG suggestive of papillary muscle originating PVC. 24 Holter was performed which showed High PVC burden (23%). During electrophysiology study PVC morphology as same as the clinical morphology, RBBB in V1; transition in V3; - in Lead II, III; + in 1, - in avL. The LV geometry was created using Deca polar catheter. The PVCs was mapped using Ablation catheter. Earliest activation signals were seen -54ms preceding the PVC at lateral side of LV postero-medial PM. Using intra cardiac echo for catheter stability RF ablation was performed at 30-40W; 17cc. Each lesion was delivered targeting an impedance drop of 10%. This resulted in termination of the PVCs.

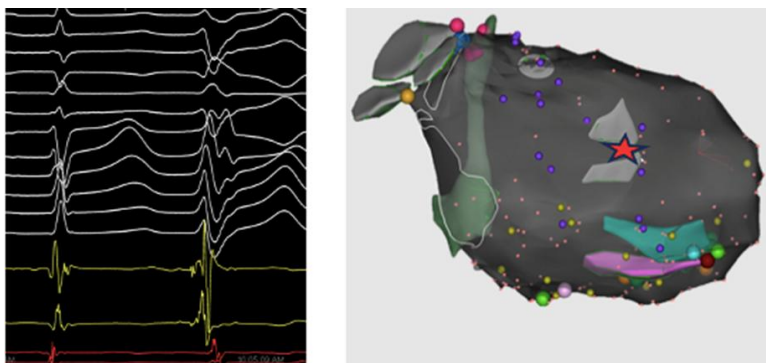


Fig (10): A- Earliest activation, B- 3 d mapping

3. Discussion

Papillary muscles are one of the triggering source for high burden of PVCs or VTs in the context of ischemic or non-ischemic heart. Identifying and ablating on this site is quite difficult because papillary muscles are originating from deep intramural sites ^[2] and their constant motion during cardiac cycle, anatomic variations and a complex Purkinje Fiber–muscular interface within the papillary muscle make ablation at this site particularly difficult. ^[3] In this case series of 10 patients PM PVCs/ VT were successfully targeted using the comprehensive mapping strategy which includes activation mapping, pace mapping and intracardiac echo. Catheter ablation of papillary muscle arrhythmias are performed at the site of earliest activation which was identified by the activation mapping using multi electrode catheter (HD grid) & pace map match. Intra cardiac echo place a crucial role for the assessment of catheter and tissue contact, identifies the site of origin, differentiating papillary muscle foci from adjacent endocardial structures and gives us a procedural safety by allowing continuous visualization during ablation.

The requirement of irrigated radiofrequency ablation to obtain sustained arrhythmia suppression in deep intramyocardial origin of the arrhythmogenic foci ^[4] RF ablation was performed for all the patients using irrigated tip catheter with the power of 35W, 43 deg with the impedance drop of 10 ohms. In the presence of multiple exit sites and variable QRS morphologies, in such cases ablation at the earliest activation site combined with targeting adjacent regions was performed to achieve durable suppression. Acute procedural success was obtained in 80% of the cases with termination of VT/ significant reduction of PVC burden.

4. Conclusion

During follow up most of the patients were demonstrated sustained arrhythmia control and symptomatically improved. Adequate catheter stability and comprehensive lesion delivery is essential to achieve durable success. This case series demonstrates that RF ablation of papillary muscle PVC/ VT is feasible, safe and effective when guided by integrated electroanatomic mapping, intra cardiac echocardiography and should be a valuable therapeutic option for symptomatic patients and with high PVC burden arising from papillary muscle.

References

- [1] Anatomy, Thorax, Heart Papillary Muscles, Natalie L. Rich, Yusuf S. Khan 1In: StatPearls Treasure Island (StatPearls Publishing; 2025 Jan.2023 Jul 24.
- [2] Papillary Muscle Ventricular Tachycardia or Ectopy: Diagnostics, Catheter Ablation and the Role of Intracardiac Echocardiography Josef Kautzner, Petr Peichl
- [3] Spectrum of ventricular arrhythmias arising from papillary muscle in the structurally normal heart, Naksuk, N, Kapa, S, Asirvatham, S.J, Card Electrophysiol Clin. 2016; 8:555-565
- [4] Ventricular tachycardia originating from the posterior papillary muscle in the left ventricle: a distinct clinical syndrome, Doppalapudi H, Yamada T, McElderry HT et al, Circ Arrhythm Electrophysiol. 2008; 1:23–9. doi: 10.1161/CIRCEP.107.742940