



Case Report

Incidentally found tumour in the chest in a child

Femela Muniraj¹, Sunder², Karthikeyan³, Raghavi Nanthakumar⁴

¹Consultant Pathologist - Laboratory Services, Radial Road, Chennai, Tamil Nadu

²Director – Lung transplantation & Senior Cardiothoracic & Heart-Lung Transplant Surgeon, Radial Road, Chennai, Tamil Nadu

³Consultant Cardiothoracic & Heart-Lung Transplant Surgeon, Radial Road, Chennai, Tamil Nadu

⁴Senior Registrar - Laboratory Services, Radial Road, Chennai, Tamil Nadu

Abstract

Background: Pediatric chest tumors are rare and often present diagnostic challenges due to their varied etiology and frequently asymptomatic nature. Incidental detection on routine imaging is common, and while many are benign, a significant proportion (up to 50% in some series) can be malignant. Early identification and compartmental localization are critical for guiding further management.

Key words: Tumor; Ganglioneuroma; Schwannian neural cells

1. Case Presentation

Incidentally found to have a large intrathoracic mass on a routine chest X-ray. He was referred to our tertiary center for further evaluation and management. A thoracotomy was performed, and intraoperatively the tumour was found to occupy more than half of his chest cavity, causing significant collapse of the left lung. The surgery was uneventful, and postoperative X-rays showed excellent re-expansion of the lung. The child recovered well and was discharged home just four days after the procedure.

Citation: Femela Muniraj, Sunder, Karthikeyan, Raghavi Nanthakumar. Incidentally found tumour in the chest in a child. *Kauverian Med J.* 2026;3(3):40-42.

Academic Editor: Dr. Venkita S. Suresh

ISSN: 2584-1572 (Online)



Copyright: © 2026 by the authors. Submitted for possible open access publication under the terms and conditions.

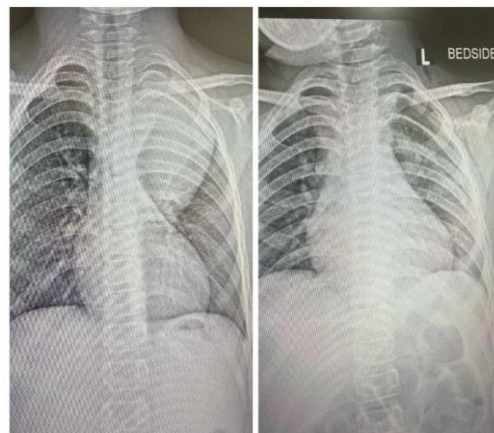


Fig (1): Chest X-ray showing the intrathoracic mass – Preoperative (left); postoperative (right)

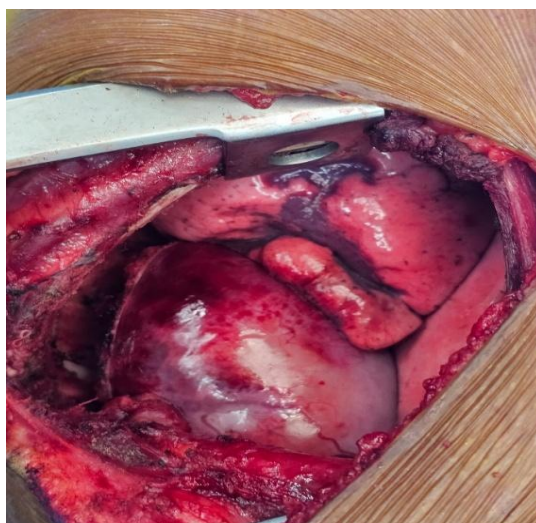

Fig (2): Intraoperative photograph of the intrathoracic mass

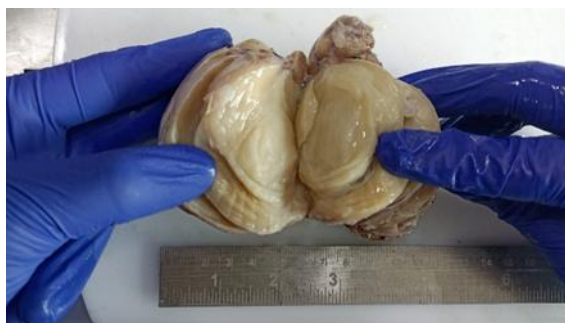

Fig (3): Macroscopic picture of the tumor

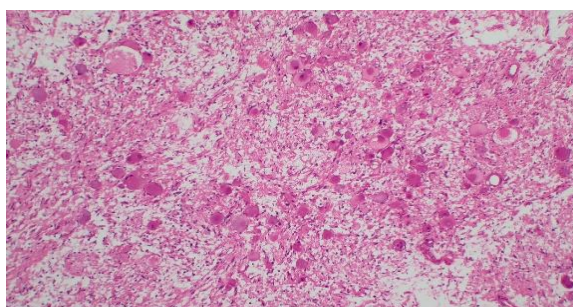


Fig (4): Microscopic view of the tumor showing two components – The Schwannian neural cells and the ganglion cells (H & E, x100)

2. Pathology

The tumor was diagnosed as 'Ganglioneuroma' and confirmed with immunohistochemistry. Ganglioneuroma is a benign tumor composed of benign Schwann cells and ganglion cells.

3. Overview

Ganglioneuromas are rare, benign, fully differentiated tumors arising from neural crest-derived sympathetic ganglion cells. They occur most commonly in children and adolescents, typically between 10–20 years, though younger cases are reported¹. Intrathoracic (posterior mediastinal) ganglioneuromas account for a significant proportion of mediastinal neurogenic tumors in children.

Diagnosis: *Ganglioneuroma*

Management: Complete surgical excision is curative; incomplete removal rarely leads to recurrence ^[3]. No chemotherapy or radiotherapy indicated for typical ganglioneuroma.

Prognosis: Excellent prognosis. Malignant transformation is exceedingly rare^[3].

References

1. Shimada H, Ambros IM, Dehner LP. Terminology and classification of neuroblastic tumors. *J Pediatr Hematol Oncol.* 1999;21(6):430-5.
2. Takahashi T, Morikawa T, Yamaguchi M. Mediastinal neurogenic tumors in children. *Ann Thorac Surg.* 1998;65(3):731-5.
3. Georger B, Hero B, Berthold F. Clinical management of peripheral neuroblastic tumors. *Pediatr Hematol Oncol.* 1999;16(2):107-22.